



PRESENTING CLINICAL SIGNS

History: Pre-anesthetic ECG showed increased R wave amplitude.

DATE

2/3/23

ECHOCARDIOGRAPHIC FINDINGS

2D, M-mode, and Doppler study.

PERFORMED BY:

Sarah Pender, CVT

INTERPRETED BY

Keith Blass, DVM,
MS, DACVIM
(Cardiology)

Left atrial size is normal. The mitral valve appears normal, though trace mitral regurgitation is present. Left ventricular wall thickness is normal. Left ventricular internal dimensions are normal. Left ventricular systolic function is normal. The aorta and aortic valve appear normal, though there is mildly increased flow velocity in the ascending aorta. Right atrial and right ventricular dimensions are normal. The tricuspid valve appears normal, though trace tricuspid regurgitation is present. The pulmonary artery and pulmonic valve appear normal, though trivial pulmonic insufficiency is present. No shunting lesions are visualized. No pericardial effusion or cardiac masses are seen.

PATIENT

Zeke Kahl

LA - 35.5 mm
IVSd - 10.5 mm
LVPWd - 9.9 mm
LVIDd - 35.4 mm
LVIDs - 23.6 mm
FS - 33%
RA - 28.8 mm
LVOT - 1.75 m/s
RVOT - 1.40 m/s

SPECIES

Canine

ASSESSMENT/RECOMMENDATIONS

BREED

Boxer

This examination demonstrates trace regurgitation of blood across Zeke's mitral and tricuspid valves, which could either be normal physiologic variants or indicators of the presence of very mild valvular dysplasia. The hemodynamic effects of the regurgitations are negligible, and Zeke's current risk for the development of clinical signs secondary to them is low.

SEX

MI

Zeke's elevated R wave amplitude is likely a normal variant, as no evidence of left ventricular enlargement is appreciated in this exam.

Zeke's cardiovascular risk for general anesthesia is low based on this exam, though avoidance of the use of alpha-2 agonists in the anesthetic protocol may be warranted as a precaution.

AGE

7 mo

A recheck echocardiogram may be warranted in 6-9 months to make sure that Zeke's regurgitations aren't worsening.

WEIGHT

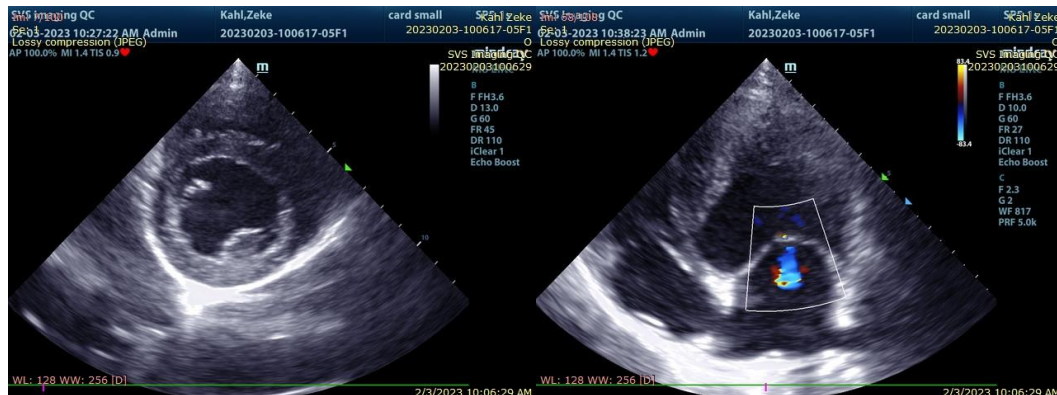
58 lb

HOSPITAL NAME

SVS Imaging QC

REFERRING VET

Dr. Glispie





DATE

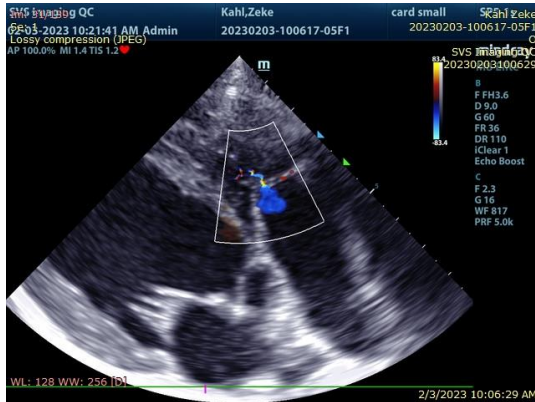2/3/23

PERFORMED BY:

Sarah Pender, CVT

INTERPRETED BY

Keith Blass, DVM,
MS, DACVIM
(Cardiology)



The information and recommendations provided are based on the images presented by the referring veterinarian. No evaluation can be communicated regarding pathology that was not visible in the image/video clips provided.

PATIENT

Thank you for this referral. If the clinical or image interpretation does not parallel your findings or if I can be of any further assistance please contact me.

Zeke Kahl

SPECIES

Keith Blass, DVM, MS, DACVIM (Cardiology)
KeithBlass@gmail.com
631-804-5754

Canine

BREED

Boxer

SEX

MI

AGE

7 mo

WEIGHT

58 lb

HOSPITAL NAME

SVS Imaging QC

REFERRING VET

Dr. Glispie